

Erratum

The effect of Theiler's murine encephalomyelitis virus (TMEV) VP1 carboxyl region on the virus-induced central nervous system disease

Andrea Serkowski, Benjamin Shim and Raymond P Roos

Journal of NeuroVirology (1995) 1: 101–110

In the above article Figure 2 was printed incorrectly. The figure is correctly reproduced below.

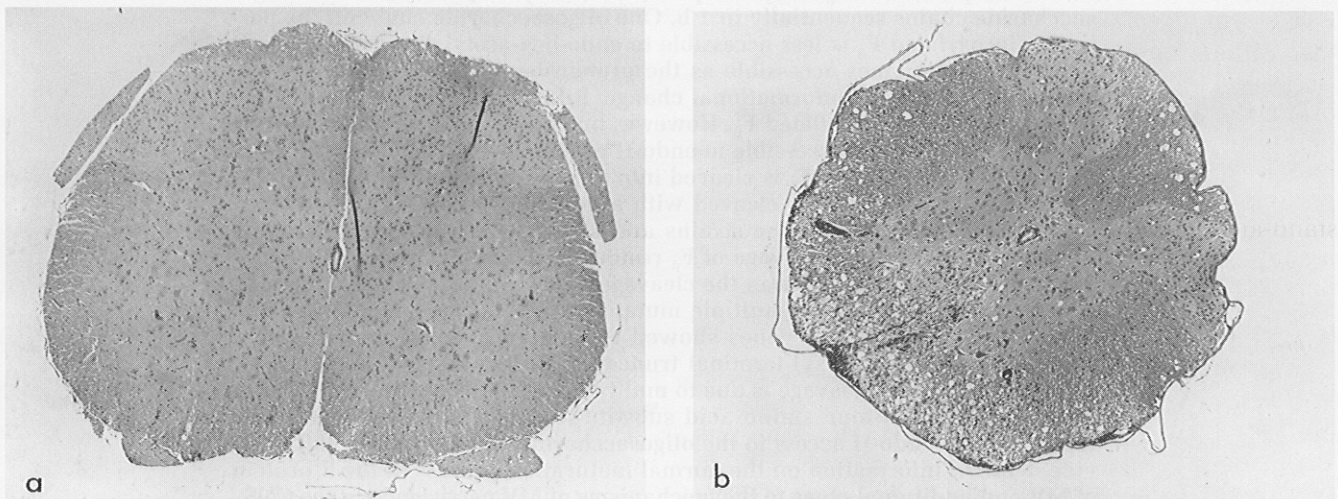


Figure 2 Histopathology of mouse spinal cords harvested 3 months after intracerebral inoculation with wild type DA or DA-VP1-268 virus. (a) The spinal cord from a representative mouse inoculated with DA-VP1-268 virus shows no histopathology. (Hematoxylin–eosin stained paraffin section; magnification, $\times 20$). (b) The spinal cord from a representative mouse inoculated with wild-type DA virus which demonstrates an accumulation of inflammatory cells and extensive myelin loss. (Hematoxylin–eosin stained paraffin section; magnification, $\times 16$).