

Case Report

Severe neurological complications in association with Epstein-Barr virus infection

Eleonora PM Corssmit¹, Maureen A Leverstein-van Hall^{2,4}, Peter Portegies³ and Piet Bakker¹

¹Departments of Internal Medicine, ²Microbiology and ³Neurology of the Academic Medical Center, University of Amsterdam, Meibergdreef 9, 1105 AZ Amsterdam, The Netherlands

Involvement of the nervous system in infectious mononucleosis is common. About 50% have headache on presentation. Neck stiffness without meningitis is a frequent finding. Severe neurological complications are rare though, occurring in fewer than 0.5%. We describe two patients with unusual and severe neurological complications in association with serological evidence of EBV-infection: a 32-year old female developed a bilateral optic neuritis combined with a transverse myelitis and a 72-year old man developed mononeuritis multiplex, autonomic neuropathy and a salt-wasting nephropathy.

Keywords: Epstein Barr virus; neuritis; myelitis; hyponatraemia

Introduction

The nervous system is not infrequently involved in patients with infectious mononucleosis (Silverstein *et al*, 1972; Grose *et al*, 1975) with an estimated incidence varying between 0.37 to 7.3% (Silverstein *et al*, 1972). The spectrum of neurological illness associated with Epstein-Barr virus infection is found in Table 1. When only cerebrospinal fluid abnormalities are considered, an incidence of 26.5% has been reported (Pejme, 1964). According to Silverstein and colleagues (Silverstein *et al*, 1972), the neurological complications of infectious mononucleosis have a good prognosis with complete recovery observed in 85% of cases. However a mortality rate of 11% has been reported by others (Davie *et al*, 1963). In the presence of severe polyradiculoneuritis, the mortality rate may rise as high as 25%, likely the consequence of autonomic dysfunction with associated cardiac arrhythmias (Davie *et al*, 1963; Ringelstein *et al*, 1984). In this report, we describe two patients with severe neurological manifestations associated with Epstein-Barr virus (EBV) infection.

Case histories

Patient 1

A 32-year old woman presented with malaise and fatigue of several weeks duration, fever (39°C) and

pharyngitis. She experienced paraesthesiae extending from her feet to her navel and diminished strength in her legs, followed by blurred vision and inability to urinate. On admission, the temperature was 36.8°C, pulse 70, blood pressure 110/80 mm Hg. Physical examination revealed pharyngitis but no other abnormalities. Neurological examination revealed bilateral papilledema, her vision was 1/300 (examination by the use of the Snellen test charts; 1/300, i.e., recognizes hand movement at a distance of 1 m) on both sides. Ocular motility and other cranial nerve functions were preserved. She had a paresis of abdominal and paravertebral muscles, a flaccid paralysis of both legs with absent knee, ankle and plantar reflexes, hypesthesia below T1 on the right and below T4 on the left and hypalgesia below T6 on the right and below T8 on the left.

Laboratory investigations showed normal values for the erythrocyte sedimentation rate (ESR), haemoglobin, platelet count, serum electrolytes, renal and liver function. Leukocytes were $14.4 \cdot 10^9/l$ with a normal differentiation. CSF-analysis revealed 502 white cells per mm^3 (50% monocytes/lymphocytes and 50% neutrophils), a total protein of 750 mg/dl, glucose 1.5 mmol/l. Viral, bacterial cultures, syphilis and borrelia antibody tests were negative. Serum and CSF-findings were compatible with an acute Epstein Barr Virus (EBV)-infection (Table 2). MRI-scan of the brain showed multiple small white matter hyperintensities periventricularly. MRI-scan of the spinal cord showed hyperintense areas from C4–C6 and from

Correspondence: EPM Corssmit

⁴Current address: Department of Microbiology, University of Utrecht, The Netherlands

Received 8 April 1997; revised 13 June 1997; accepted 30 September 1997

Table 1 Neurological complications of EBV infection (Aita, 1972)

— Meningitis
— Encephalitis
— Cranial nerve neuritis
— Myelitis
— Polyneuritis
— Mononeuritis
— Autonomic neuropathies

Th6–Th12 (Figure 1). Visual evoked potentials were abnormal on the left side: latency P3: OS 126,5 ms (OD 106 ms) and amplitude: OS 0.6 μ V (OD 3–7 μ V).

This patient had a bilateral optic neuritis combined with a transverse myelitis (Devic's disease or neuromyelitis optica) occurring in association with an acute EBV infection. She was treated with methylprednisolon intravenously

Table 2 Antibody titers to Epstein-Barr virus (EBV) in serum and CSF: patient 1–2, 3.5 and 4 w, patient 2–6, 8, 10, 14 and 46 w after the start of symptoms

	2 w	Patient 1				Patient 2			
		3.5 w	4 w		6 w	8 w	10 w	14 w	46 w
Blood									
VCA-IgM	1:80	1:40	neg		neg	neg	neg	neg	neg
VCA-IgG	1:80	1:80	pos		pos	1:160	1:160	1:160	pos
anti-EA	<1:10	<1:10	NT		1:320	1:320	1:320	1:320/640	1:40
anti-EBNA	neg	neg	pos		NE	NE	NE	NT	pos
HA	pos	pos	NT		NT	NT	NT	NT	NT
CSF									
VCA-IgM	pos		± pos		neg				
VCA-IgG	neg		neg		pos				
anti-EA	neg		neg		1:2				
anti-EBNA	neg		neg		pos				
HA	NT		NT		NT				

NT = not tested; NE = not (possible to be) evaluated; EA = early antigen; EBNA = Epstein-Barr nuclear antigen; VCA = viral capsid antigen; HA = test for heterophil antibodies.

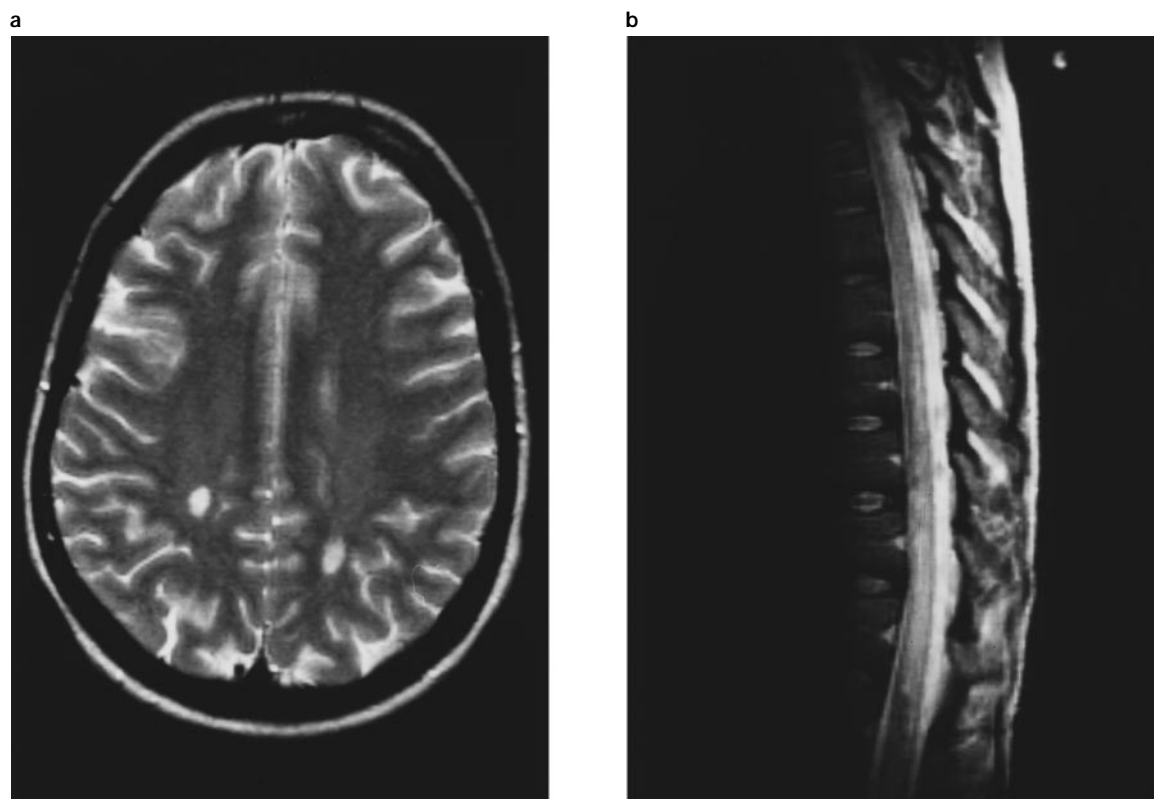


Figure 1 MRI-scan of cerebrum (a) and spinal cord (b) in patient 1 with large areas of increased signal periventricularly (a) and from T6 to T12 (b).

1000 mg/day for 3 days, followed by oral prednisone. Two weeks later her vision was 2/3 on both sides. No improvement in her paraplegia was noted after 6 weeks follow up in the outpatient clinics.

Patient 2

A 71-year old man presented with a 2 month history of a progressive burning sensation in his left thigh. Subsequently, he developed malaise and a loss of appetite resulting in 12 kg of weight loss, forgetfulness, weakness of his left leg and the right hand. The week before admission to hospital, nausea, postural dizziness, urinary hesitancy and erectile dysfunction supervened.

On examination, minimal state score was normal. Supine blood pressure was 130/90 mm Hg, pulse rate 76/minute; standing 86/65 mm Hg, pulse rate to 96/minute. Physical examination revealed cachexia but no other abnormalities. Neurological examination revealed atrophy, weakness and sensory loss of his right hand with atrophy, absent muscle stretch reflex of the triceps muscle, and hyperpathia with decreased vibratory sense of his left leg.

Electromyography showed delayed conduction velocities, compatible with mononeuritis multiplex. Laboratory investigations showed an ESR of 5 mm Hg, leukocytes $5.0 \times 10^9/L$ with 15.1% monocytes. Serum sodium 125 mmol/l, potassium 3.6 mmol/L, creatinine 50 $\mu\text{mol/L}$ and normal liver function tests. The urinary sodium excretion was 122 mmol/24 h; with a salt-depleted diet plasma sodium decreased to 119 mmol/L, whereas urinary salt excretion exceeded 100 mmol/24 h (indicating a salt-wasting nephropathy). Plasma cortisol, renin activity and aldosterone were normal. The antidiuretic hormone (ADH) level was slightly elevated at 2.0 ng/L (normal 0.2–1.5). Aldosterone, epinephrine, norepinephrine, atrial natriuretic peptide (ANP) and ADH increased after 10 min of standing, whereas renin activity and cortisol remained unchanged. The low basal plasma renin activity (0.3 ng angiotensin I production/mL/h) and the lack of the renin response to standing indicated hyporeninemic hypoaldosteronism. During the Valsalva manoeuvre, the blood pressure decreased without a return of diastolic pressure to resting values. The normally occurring overshoot of systolic and diastolic blood pressure was absent, indicating a disturbed baroreflex caused by decreased vasomotor and cardiomotor control. Since an adequate response of catecholamine release on standing was measured, a total postganglionic lesion causing autonomic neuropathy seems unlikely. Although the pathogenesis of the hyporeninemic hypoaldosteronism is not certain, disturbed sympathetic (autonomic) regulation of renin secretion can be postulated. This would also explain the salt-wasting nephropathy (Figure 2).

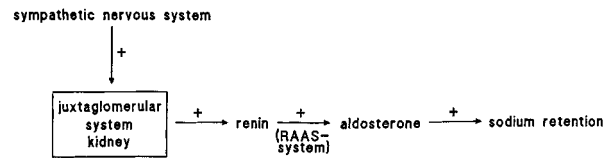


Figure 2 Autonomic control of renin secretion by the kidney. The parasympathetic system does not influence renin secretion. In case of decreased sympathetic (autonomic) stimulation of renin secretion, salt wasting and therefore hyponatremia might be the result.

Extensive examinations showed no evidence for a paraneoplastic syndrome or a systemic disease. Viral and bacterial cultures were negative, including hepatitis A and B, HSV, CMV, Varicella zoster virus, measles, mumps, coxsackie viruses and HIV. EBV-serology was positive (Table 2), with a high serotiter of anti-EA (1:320) and a positive anti-EBNA and IgG VCA in the CSF, suggesting a recrudescence of a latent infection. However, since the serological studies failed to demonstrate a seroconversion, a non-specific elevation of antibodies to EBV cannot be ruled out. The patient was treated symptomatically with sodium supplementation. During the follow up period of 46 weeks, the patient improved gradually while the EA-titer, indicative of active viral replication, decreased slowly.

Discussion

In this report, we described two patients with rare and severe neurological complications in association with EBV-infection. Patient 1 developed a bilateral optic neuritis combined with a transverse myelitis as complication of an acute EBV-infection, patient 2 a mononeuritis multiplex, autonomic neuropathy and a salt-wasting nephropathy, likely due to a recrudescence of a latent EBV infection. In patient 1, the neurological symptoms were preceded by an episode of fever and pharyngitis. In patient 2 the neurological complications were the most striking symptoms of EBV-reactivation. This patient developed a hyponatremia in the course of his disease, which might be the result of hyporeninemic hypoaldosteronism due to disturbed autonomic/sympathetic regulation of renin secretion resulting in a salt-wasting nephropathy. To our knowledge, this complication has not been previously described. The neurological complications of EBV-infection can precede the general symptoms by 3–4 weeks (Junker *et al*, 1991), however, in most cases, they coincide with the general symptoms (Gotlieb-Stematsky *et al*, 1989). A neurological complication can be the only or most striking presentation of EBV-infection (Junker *et al*, 1991), as we suggest occurred in patient 2. The spectrum

of neurological disorders associated with infectious mononucleosis varies from an acute mononeuritis to a severe polyradiculomeningoencephalitis. Transverse myelitis is a rare complication mostly seen in young patients (Junker *et al*, 1991). Some of these patients develop a polyradiculitis (Gotlieb-Stematsky *et al*, 1989). Different neuropathies can be found: mononeuropathies, brachial plexus neuropathy and autonomic neuropathy (Liveson *et al*, 1974; Watson *et al*, 1976; Mohanaruban *et al*, 1986). Cranial nerve abnormalities, including optic neuritis and Bell's palsy, sometimes bilateral (Weintraub *et al*, 1976, 1977; Andersson *et al*, 1985) may be seen as in patient 1. The pathogenesis of the neurological complications in EBV-infection is still a matter of debate: it is speculated that during an acute or reactivated infection, EBV may enter nerve tissue by trafficking of infected B lymphocytes. Although the virus can be detected in the CNS by various techniques, immunologic mechanisms are probably more important in the pathogenesis of neurologic complications than viral replication (Strauss *et al*, 1993; Lotz *et al*, 1986; Schiff *et al*, 1982). Neuropathological studies have revealed perivascular lymphocytic infiltrates, parenchymal edema, microglial proliferation and inflammatory demyelinating lesions (Gotlieb-Stematsky *et al*, 1989). Post-infectious neurological complications like the Guillain-Barre syndrome are probably the result of a systemic immunologic reaction directed against the peripheral nerves resembling an auto-immune demyelinating disease. EBV-infection has also been mentioned in relation to acute disseminated encephalomyelitis (ADEM) or postviral encephalomyelitis. These cases had a relapsing course, with rapidly changing white matter lesions on MRI (Sjoji *et al*, 1992). The importance of immunologic mechanisms have implications for therapy. The treatment is generally supportive. Improvements with corticosteroids have been described in placebo-controlled trials (Prout *et al*, 1966), but new onset of severe neurologic complications like encephalitis has also been reported (Waldo, 1981), hampering general use of steroids in the treatment of EBV-infection. These complications were possibly due to corticosteroid-induced inhibition of EBV-specific cellular immune responses and increased viral replication (McGowan, 1992). Acyclovir was not efficacious in a randomized, double-blind, placebo-controlled trial (van der Horst *et al*, 1991), whereas we could not find randomized placebo-controlled data on the effects of gancyclovir. Interferon alpha decreased the incidence of shedding of EBV by renal allograft recipients in a prophylactic placebo-controlled study but it has not been widely used for ongoing infection (Cheeseman *et al*, 1980). Most patients recover completely within weeks to months. Because of the severity of symptoms in patient 1, we tried high doses of methylprednisolone followed

by oral prednisone in patient 1 which resulted in an improved visual acuity but did not improve her paraparesis.

Acknowledgements

We thank A Smit and W Wieling for performing the autonomic nervous system tests.

References

- Andersson J, Sterner G (1985). A 16-month-old boy with infectious mononucleosis, parotitis and Bell's palsy. *Acta Paediatr Scand* **74**: 629–632.
- Aita JA (1972). Neurological manifestations of general diseases. Thomas CC, Springfield, Illinois, pp 554–555.
- Cheeseman SH, Henle W, Rubin RH (1980). Epstein-Barr virus infection in renal transplant recipients: Effects of anti-thymocyte globulin and interferon. *Ann Intern Med* **93**: 39–42.
- Davie JC, Ceballos R, Little SC (1963). Infectious mononucleosis with fatal neuritis. *Arch Neurol* **9**: 265–272.
- Gotlieb-Stematsky T, Arlazoroff A (1989). Epstein-Barr virus. In: *Handbook of clinical neurology*. Vinken PJ, Bruyn GW, Klawans HL, (eds). Amsterdam: Elsevier Science Publishers, pp 249–261.
- Grose C, Henle W, Feorini PM (1975). Primary Epstein-Barr-virus infections in acute neurologic diseases. *N Engl J Med* **292**: 392–395.
- Junker AK, Roland EH, Hahn G (1991). Transverse myelitis and Epstein Barr virus infection with delayed antibody responses. *Neurology* **41**: 1523–1524.
- Liveson JA, Goodgold J (1974). Mononeuritis multiplex associated with infectious mononucleosis. *Can J Neurol Sci* **1**: 203–205.
- Lotz M, Tsoukas CD, Fong S, Dinarello CA, Carson DA, Vaughan JH (1986). Release of cytokines after Epstein Barr virus infection in vitro. I. Sources of kinetics of production of interferons and interleukins in normal humans. *J Immunol* **136**: 3636–3642.
- McGowan Jr JE, Chesney PJ, Crossley KB, LaForce FM (1992). From the Infectious Diseases Society of America: Guidelines for the use of systemic glucocorticoids in the management of selected infections. *J Infect Dis* **165**: 1–13.
- Mohanaruban K, Fisher DJH (1986). A combination of cranial and peripheral nerve palsies in infectious mononucleosis. *Postgrad Med J* **62**: 1129–1130.
- Pejme J. Infectious mononucleosis (1964). *Acta Med Scand* **413** (suppl): 1–83.
- Prout C, Dalrymple W (1966). A double-blind study of eighty-two cases of infectious mononucleosis treated with corticosteroids. *J Am Coll Health Assoc* **15**: 62–66.
- Ringelstein EB, Sobczak H, Pfeifer B, Hacke W (1984). Polyradiculomeningoencephalitis durch Epstein-Barr-Virusinfektion. Darstellung eines Falles mit todlichem Ausgang. *Fortschr Neurol Psychiatr* **52**: 73–82.
- Silverstein A, Steinberg G, Nathanson M (1972). Nervous system involvement in infectious mononucleosis. *Arch Neurol* **26**: 353–358.

- Schiff JA, Schaefer JA, Robinson JE (1982). Epstein-Barr virus in cerebrospinal fluid during infectious mononucleosis encephalitis. *Yale J Biol Med* **55**: 59–63.
- Sjoji H, Kusuvara T, Honda Y, Kojima K, Abe T, Watanabe M (1992). Relapsing acute disseminated encephalomyelitis associated with chronic Epstein-Barr virus infection: MRI findings. *Neuroradiology* **34**: 340–342.
- Strauss SE, Cohen JL, Tosato G, Meier J. NIH conference (1993). Epstein-Barr virus infections: biology, pathogenesis, and management. *Ann Intern Med* **118**: 45–58.
- van der Horst C, Joncas J, Ahronheim G, Gustafson N, Stein G, Gurwith M, Fleisher G, Sullivan J, Sixbey J, Roland S, Fryer J, Champney K, Schooley R, Sumaya C, Pagano JS (1991). Lack of effect of peroral acyclovir for the treatment of infectious mononucleosis. *J Infect Dis* **164**: 788–792.
- Waldo RT (1981). Neurologic complications of infectious mononucleosis after steroid therapy. *South Med J* **74**: 1159–1160.
- Watson P, Ashby P (1976). Brachial plexus neuropathy associated with infectious mononucleosis. *Can Med Assoc J* **114**: 758–767.
- Weintraub MI. Bilateral facial palsy (1977). A rare presentation of infectious mononucleosis. *Clin Pediatr (Phila)* **16**: 1158–1159.
- Weintraub MI (1976). Facial diplegia. *Arch Otolaryngol* **102**: 311–312.