

Case Report

Dengue virus in the brain of a fatal case of hemorrhagic dengue fever

Celso Ramos¹, Gilma Sánchez¹, Rogelio Hernández Pando², Javier Baquera², Dalia Hernández¹, Javier Mota¹, José Ramos¹, Adrián Flores³ and Eduardo Llausás⁴

¹Depto. de Arbovirus, Centro de Investigaciones sobre Enfermedades Infecciosas, Instituto Nacional de Salud Pública, Cuernavaca, Morelos; ²Depto. de Patología, Inst. Nal. de la Nutrición, México, D.F.; ³Fac. de Medicina, Univ. Aut. de Sinaloa, Culiacán, Sin.; ⁴Depto. de Infectología, Hospital Pediátrico de Sinaloa, Culiacán, Sin., Mexico

Neurologic complications associated with dengue fever are in general unusual. However, recent reports evidence more frequent neurologic alterations. In Mexico, neurologic involvement has not been reported in dengue cases. This report demonstrates the detection of dengue virus in the brain of a fatal case of dengue hemorrhagic fever. Serotype 4 was detected by immunohistochemistry and by RT-PCR in the inferior olivary nucleus of medulla and in the granular layer of cerebellum. Immunoreactivity was observed in neurons, astrocytes, microglia and endothelial cells. Our results emphasize the importance of neurologic manifestations in patients with dengue fever.

Keywords: dengue virus; human brain; hemorrhagic fever

Introduction

Dengue viruses are members of the family Flaviviridae which includes neurotropic viruses such as Japanese encephalitis virus, St Louis encephalitis virus and Murray Valley encephalitis virus (Porterfield, 1986). Neurologic alterations associated with dengue hemorrhagic fever have been reported mainly in endemic countries in Southeast Asia, the symptoms of which include headache, seizures, neck stiffness, drowsiness, depressed sensorium, behavioral disorders, delirium, paralysis and cranial nerve palsies (Gubler *et al*, 1984; Sumarmo *et al*, 1978; Kho *et al*, 1981; Sumarmo *et al*, 1983; Row *et al*, 1996; Patey *et al*, 1993; Thakare *et al*, 1996; Hendarto and Hadinegoro, 1992). Marked neurologic symptoms were noted in one fatal case of dengue shock syndrome which occurred during the outbreak of dengue in 1987 in Rio de Janeiro, Brazil (Chimeli *et al*, 1990). IgM antibodies against dengue virus in both cerebrospinal fluid (CSF) and sera were detected by Chen *et al* in Taiwan patients

(Chen *et al*, 1991). Lum *et al* (1996) reported in Malaysia six confirmed cases of dengue with a clinical picture of encephalitis; dengue 3 was isolated from CSF of four cases, and in one case, dengue 2 was detected by the polymerase chain reaction in both the CSF and blood. Bhoopat *et al* (1996) detected dengue antigen by immunohistochemical studies in frozen human organs from autopsies; a strong reactivity was found in hematopoietic cells and in cerebral cortex neurons, Purkinje cells, choroid plexus and blood vessels, astrocytes and microglia. More recently, Miagostovich *et al* (1997) published a retrospective study of fatal dengue cases in Brazil which demonstrated the presence of dengue virus antigens in the brains of three fatal cases, however, information regarding dengue serotype was not provided. In spite of the recent increases of dengue cases in Mexico, neurologic involvement has not been reported in dengue patients (General Directorate of Epidemiology/Mexico, 1996).

This study reports the presence of dengue virus in the brain of a fatal case of dengue hemorrhagic fever in Mexico. In 1995, a 17-year-old male was admitted to the Intensive Care Service at the Pediatrics Hospital in Culiacán, Sinaloa (Mexico) with the diagnosis of Dengue Hemorrhagic Fever (DHF). One week before admission he presented fever, myalgia, arthralgia, vomiting and headache and 1 day before

Correspondence: C Ramos

Depto. de Arbovirus, Centro de Investigaciones sobre Enfermedades Infecciosas, Instituto Nacional de Salud Pública, Av. Universidad No. 655, Col. Santa María Ahuacatlán 62508 Cuernavaca, Morelos (Mexico)

In memory of Dr Bernard N. Fields for his wise teaching in neurovirology

Received 12 January 1998; revised 4 March 1998; accepted 23 March 1998

hospitalization he presented generalized seizures and coma. Upon physical examination, he was diaphoretic, with fever (39°C), hypotense, and presented tachycardia and generalized petechial hemorrhages in the skin and melena. Unfortunately the patient evolution was fulminant, so it is not possible to add more clinical information.

The laboratory studies showed mild leukocytosis, normocytic anemia and accentuated thrombocytopenia. The patient died 1 day after admission with hypovolemic shock and bleeding by nose, mouth and in venopuncture sites. The patient's serum was not available for serologic and virologic studies; however, the diagnosis of dengue was based on clinical and epidemiological data. This case was reported during the epidemic of dengue hemorrhagic fever (DHF) in Sinaloa in 1995, when 13 000 cases of dengue fever, 177 cases of DHF and four fatalities, were recognized (General Directorate of Epidemiology/Mexico, 1996).

A complete autopsy was performed and tissue sections from all over the body were fixed in 10% formaldehyde and embedded in paraffin. Sections 5 μ width were stained with hemotoxylin/eosin.

Dengue virus was detected in brain tissue through immunohistochemical analysis. Tissues from the superior frontal gyrus, fourth temporal gyrus, mesencephalon, pons, medulla and cerebellum were deparaffined, rehydrated in alcohol and digested with trypsin 0.02% in PBS for 10 min at room temperature. The endogenous activity of peroxidase was blocked with 3% H₂O₂ in methanol. Brain sections were incubated overnight at 4°C with biotinylated-human polyclonal antibodies against dengue virus diluted 1:5 in PBS. The bound antibodies were revealed using a streptavidin-peroxidase conjugate diluted at 1:250. Additionally, sections from cerebellum and medulla were incubated overnight at 4°C with monoclonal antibodies specific to dengue virus serotype 4 (1H10) and diluted at 1:5 in PBS; Rabbit anti-mouse polyclonal antibodies conjugated to peroxidase and the Tiramide Signal Amplification System (New England Nuclear) were used to reveal the bound antibodies. From the same brain tissue embedded in paraffin blocks, total RNA was extracted according to the procedure described by Jiang *et al* (1995).

Dengue virus RNA was amplified according to the procedure described by Lanciotti *et al* (1992). The DNA bands were stained with ethidium bromide (0.1 mg/ml) and observed with a UV light lamp; PCR products size for each virus was determined using Hae III-digested ϕ × 174 DNA (GIBCO, BRL) as molecular weight standard. Dengue prototypes (Dengue 1, Hawaii; Dengue 2, NGC; Dengue 3, H-87 and Dengue 4, H-241) and negative controls were included for each reaction.

The complete necropsy study showed bilateral pleural bloody fluid collection, hemorrhagic ascitis and pericarditis with multiple petechial hemorrhages and ecchymosis on the surface of the mesentery heart, lungs, kidneys, larynx and pharyngeal mucosa. Massive amounts of bloody liquid were found in the stomach and small intestine lumen. The heart was dilated and flabby. The brain showed slight meningeal opacity, vein congestion and generalized edema with bilateral uncus herniation. Light microscopy analysis revealed patchy lymphocyte infiltrate in the interstitial myocardial tissue with necrosis of individual muscle fibers. Particularly distinctive was mononuclear inflammatory infiltrate below hyperplastic and disrupted venular endothelium with extensive hemorrhagic areas in the lamina propria of stomach and intestines. Focal inflammatory infiltrate constituted by activated lymphocytes and macrophages was observed surrounding the leptomeningeal veins and occasional eosinophilic neurons were seen, however, distinctive histopathological features of brain viral infection such as inflammatory perivascular cuffs, neuronal death with neurophagia and activated microglia were not observed.

Neurons, astrocytes, microglia and endothelial capillary cells from the inferior olivary nucleus in the medulla and in the granular layer from the cerebellum showed strong immunostaining with both polyclonal human anti-dengue antibodies and with mouse monoclonal anti-dengue 4 virus (Figure 1). RT-PCR product for dengue 4 (392 bp) was observed in the inferior olivary nucleus of medulla, and in the granular layer of cerebellum (Figure 2).

Neurologic complications associated with dengue fever are in general unusual (Gubler *et al*, 1984). However, recent reports evidence a more frequent

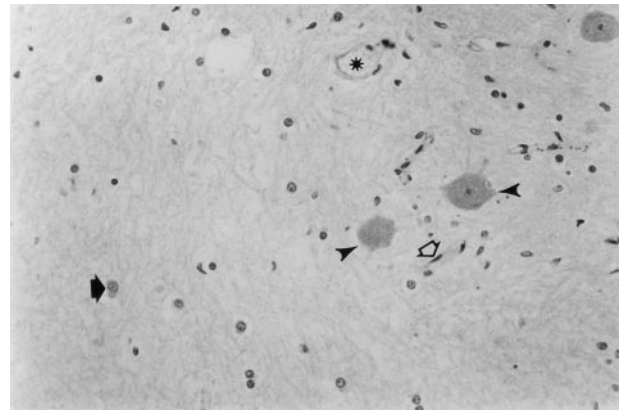


Figure 1 Positive immunostaining from the inferior olivary nucleus of medulla using a polyclonal antibody against dengue virus. Strong immunoreactivity is observed in neurons (black arrow head), astrocytes (black arrow), microglia (white arrow) and endothelial capillary cells (asterisk). The same pattern was observed using a monoclonal antibody against dengue 4.

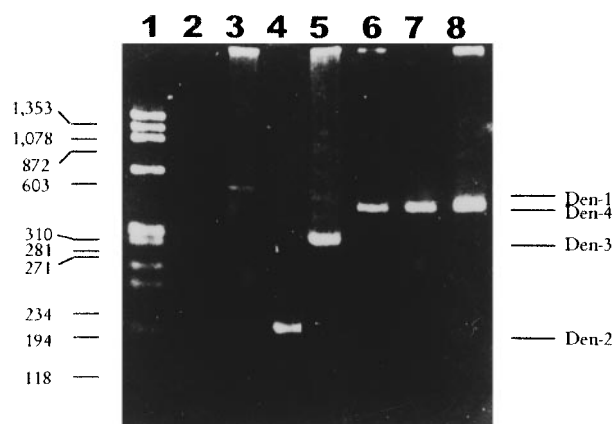


Figure 2 Detection of dengue virus by RT-PCR analysis in brain of a fatal case of hemorrhagic dengue fever. Lanes: 1 (molecular weight standards), 2 (negative control), 3 (Den 1 prototype Hawaii), 4 (Den 2 prototype NGC), 5 (Den 3 prototype H-87), 6 (Den 4 prototype H-241), 7 (medulla, inferior olivary nucleus), 8 (cerebellum, granular layer). PCR products from dengue virus prototypes (Den 1, 482 bp; Den 2, 119 bp; Den 3, 290 bp and Den 4, 392 bp), are indicated in the left side of figure.

association of neurologic alterations in dengue cases (Row *et al*, 1996; Patey *et al*, 1993; Thakare *et al*, 1996; Hendarto and Hadinegoro, 1992). The pathophysiology of neurologic involvement in human cases of dengue has been attributed to factors such as cerebral edema, cerebral hemorrhage, hyponatremia, fulminant hepatic failure with portosystemic encephalopathy, cerebral anoxia, microcapillary hemorrhage and release of toxic products (Gubler *et al*, 1984). Certain neurological signs and symptoms are classically observed during acute infection such as headache, dizziness, delirium, sleeplessness, mental irritability and depression. Postinfection disorders such as epilepsy, tremors, amnesia, dementia and maniac psychosis, have also been recognized (Jimenez *et al*, 1988). Based on studies in southeast Asia, encephalopathy associated with classic dengue fever can occur in up to half of the cases (Nelson, 1960). Sumarmo *et al* (1983) reported encephalitic symptoms in many fatal cases of dengue which occurred in Indonesia (Sumarmo *et al*, 1983). The number of cases affected with dengue virus reported with alterations in the central nervous system could be related to the geographic area. In spite of recent increment of dengue cases in Mexico, neurologic involvement has not been reported (General Directorate of Epidemiology/Mexico, 1996). To our knowledge, the present report deals with the first fatal hemorrhagic case with neurologic symptoms and dengue virus detection in a patient's brain through immunohistochemistry and RT-PCR analysis. Our results are similar to those of Bhoopat *et al* (1996)

who detected dengue antigens through immunohistochemical studies of frozen human organs from autopsies; these authors found strong immunostaining in hematopoietic cells and in cerebral cortex neurons, Purkinje cells, astrocytes and microglia, as well as in choroid plexus and blood vessels. In the present case, and in spite of absence of histological damage characteristic of viral infection, this study demonstrated through immunohistochemical analysis the presence of dengue virus in brain by using human polyclonal antibodies against dengue and also with a monoclonal antibody (1H10) specific for dengue virus serotype 4 in neurons, astrocytes and microglia from the medulla (olivary inferior nucleus) (Figure 1) and cerebellum (granular layer).

The results of the immunohistochemical analysis were corroborated by molecular analysis, which was positive using specific primers for dengue 4 by RT-PCR in medulla and cerebellum (Figure 2). An additional proof on the presence of dengue 4 was obtained when PCR products from cerebellum and medulla were digested with the restriction enzyme *NlaIII*; a similar digestion pattern was obtained with prototype of dengue 4 (H-241) and with our patient (Data not shown).

Unfortunately, patient's serum sample was not available for serological and virological studies, however the diagnosis of dengue was sustained through clinical and epidemiological data (General Directorate of Epidemiology/Mexico, 1996). The diagnosis of dengue virus serotype 4 was also supported by local epidemiological data; in fact, dengue 4 associated with hemorrhagic fever has been documented in Mexico since 1984, when cases of hemorrhagic dengue, including four fatalities due to this serotype were recognized in Yucatan (Loroño *et al*, 1993).

Lum *et al* (1996) demonstrated the presence of dengue 3 in the cerebrospinal fluid and blood in most fatal cases of dengue which occurred in Malaysian children with neurologic symptoms; since the onset of encephalitis appears early in the course of illness coinciding with the viremic phase, these authors postulated that the virus crosses the blood brain barrier and directly invades the brain causing encephalitis. Our results and from other studies, emphasize the importance of neurologic manifestations in patients with dengue fever and the potential ability of dengue viruses to invade the nervous system.

Acknowledgements

This research work was partially supported by the National Council for Science and Technology (CONACYT/MEXICO, No. 1862PM). We thank Miss Claudia Gómez Cerón for typing this paper.

References

- Bhoopat L, Bhamarapravati N, Attasiri C, Yoksarn S, Chaiwun B, Khunamornpong S, Sirisanthana V (1996). Immunohistochemical characterization of a new monoclonal antibody reactive with dengue virus-infected cells in frozen tissue using immunoperoxidase technique. *Asian Pac J Allergy Immunol* **14**: 107–113.
- Chen WJ, Huang KP, Fang AH (1991). Detection of IgM antibodies from cerebrospinal fluid and sera of dengue fever patients. *Southeast Asian J Trop Med Public Health* **22**: 659–663.
- Chimeli L, Hahn MD, Netto MB, Ramos RG, Dias M, Gray F (1990). Dengue: neuropathological findings in 5 fatal cases from Brazil. *Clin Neuropathol* **9**: 157–162.
- General Directorate of Epidemiology (1996). Report/Secretary of Health, México.
- Gubler DJ, Kuno G, Waterman SH (1984). *Neurologic disorders associated with dengue fever infection*. In: Pang T, Pathmanathan R, (eds). Proceedings of the International Conference on Dengue/DHF, Kuala Lumpur, University of Malaysia Press.
- Hendarto SK, Hadinegoro SR (1992). Dengue encephalopathy. *Acta Paediatr Jpn* **34**: 350–357.
- Jiang Y-H, Davidson LA, Lupton JR, Chapkin RS (1995). A rapid RT-PCR method for detection of intact RNA in formalin-fixed paraffin-embedded tissues. *Nucleic Acids Research* **23**: 3071–3072.
- Jimenez DR, Santana JL, Ramirez-Ronda CH (1988). Neurological disorders associated to dengue infection. *Bol Assoc Med PR* **80**: 208–211.
- Kho LM, Sumarmo WH, Jahja E, Gubler DJ (1981). Dengue hemorrhagic fever accompanied by encephalopathy in Jakarta. *Southeast Asian J Trop Med Public Health* **12**: 83–86.
- Lanciotti RS, Calisher CH, Gubler DJ, Chang G, Vorndam AV (1992). Rapid detection and typing of clinical samples by using reverse transcriptase polymerase chain reaction. *Journal of Clinical Microbiology* **30**: 545–551.
- Lum LCS, Lam SK, Choy YS, George R, Harun F (1996). Dengue encephalitis: A true entity? *Am J Trop Med Hyg* **54**: 256–259.
- Loroño PMA, Farfan AJA, Rosado PEP, Kuno G, Gubler DJ (1993). Epidemic of dengue in the Yucatan, México. *Rev Inst Med Trop Sao Paulo* **35**: 449–455.
- Miagostovich MP, Ramos RG, Nicol AF, Nogueira RM, Cuzzi-Maya T, Oliveira AV, Marchevsky RS, Mesquita RP, Schtzamyr HG (1997). Retrospective study on dengue fatal cases. *Clin Neuropathol* **16**: 204–208.
- Nelson ER (1960). Haemorrhagic fever in children in Thailand: report of 69 cases. *Pediatrics* **56**: 101–108.
- Patey O, Ollivaud L, Breuil J, Lafaix C (1993). Unusual neurologic manifestations occurring during dengue infection. *Am J Trop Med Hyg* **48**: 793–802.
- Porterfield JS. (1986). Comparative and historical aspects of the Togaviridae and Flaviviridae. In: Schlesinger S, Schlesinger MJ, (eds). *The Togaviridae and Flaviviridae* Plenum Press: New York, pp 1–16.
- Row D, Weinstein P, Murray-Smith S (1996). Dengue fever with encephalopathy in Australia. *Am J Trop Med Hyg* **54**: 253–255.
- Sumarmo WH, Jahja E, Gubler DJ, Sutomeggolo TS, Sulianti SJ (1978). Encephalopathy associated with dengue infection. *Lancet* **i**: 449–450.
- Sumarmo WH, Jahja E, Gubler DJ, Suharyono W, Sorensen K (1983). Clinical observations on virologically confirmed fatal dengue infections in Jakarta, Indonesia. *Bull World Health Organ* **61**: 693–701.
- Thakare J, Walhekar B, Banerjee K (1996). Hemorrhagic manifestations and encephalopathy in cases of dengue in India. *Southeast Asian J Trop Med Public Health* **27**: 471–475.